Anaesthesia
Journal of the Association of Anaesthetists of Great Britain and Ireland
Anaesthesia, 2011, **66**, pages 840–852

transient hypocalcaemia. Hypocalcaemia, hypomagnesaemia and alkalosis are known to cause a positive Trousseau's sign [3].

As regional techniques allowing patients to be conscious during surgery become more commonplace in anaesthetic practice, we would advise practitioners not to underestimate the need for anxiolysis. Thorough exploration of patients' anxiety should be made in patients undergoing such procedures, with careful consideration given to the need for anxiolytics. Respiratory monitoring may be useful, with an increase in respiratory rate acting as a marker for hyperventilation. Anxiety not only leads to an unpleasant patient experience, but may also prevent surgical access.

S. Rastogi
W. J. Brady
University Hospital of South Manchester
Manchester, UK
Email: sachrastogi@gmail.com

No external funding or potential competing interests declared. Published with the written consent of the patient. Previously posted at the *Anaesthesia* Correspondence website: http://www.anaesthesiacorrespondence.com.

References

1 Russon K, Pickworth T, Harrop-Griffiths W. Upper limb blocks. *Anaesthesia* 2010; **65**: 48–56.
2 Pearce JM. Armand Trousseau – Some of his contributions to neurology. *Journal of the History of the Neurosciences* 2002; **11**: 125–35.
3 Aguilera IM, Vaughan RS. Calcium and the anaesthetist. *Anaesthesia* 2000; **55**: 779–90.

doi: 10.1111/j.1365-2044.2011.06846.x

Research, audit and journal policies

The editorials [1, 2] on research and audit and ethical review identify important issues that could have a serious negative impact on the dissemination of learning from clinical audit and quality improvement activities. They discussed the definition and intent of clinical audit and research, the need for ethical oversight of clinical audit and quality improvement activities, and whether or not the Research Ethics Committee (REC) or Institutional Review Board (IRB) is the only or right mechanism for the ethical oversight of clinical audit and quality improvement activities, particularly for the purposes of publication.

Possible confusion between research and audit or quality improvement has been recognised in the literature [3]. The requirement by journals for ethical review undertaken in advance of carrying out a clinical audit or quality improvement activity is likely to discourage publications of such work [3]. Therefore, is this policy in the public interest, given the recognised need to disseminate knowledge and experience related to improving the quality and safety of healthcare services? In the UK, guidance on how to identify clinical audit or quality improvement projects that need ethical scrutiny has been provided for National Health Service (NHS) organisations. Organisational mechanisms for ethical oversight have also been suggested and some adopted [4].

It may be appropriate for journal editorial boards to adopt a short list of characteristics of clinical audits or quality improvement activities for which evidence of ethical scrutiny by the author's organisation is required as a prerequisite for publication. The list could incorporate the list of situations or circumstances included in the current advice to NHS organisations. This is a more rational and less discouraging approach than imposing REC/IRB review of clinical audits and quality improvement activities being carried out in healthcare organisations.

N. Dixon
Healthcare Quality Quest Ltd
Shelley Farm
Hampshire, UK
Email: Nancy.Dixon@hqq.co.uk

The development of *Review of ethics issues related to clinical audit and quality improvement activities*, and *Ethics and clinical audit and quality improvement (QI) – a guide for NHS organisations* were funded by the Healthcare Quality Improvement Partnership (HQIP), the organisation that manages the national clinical audit programme in England. No other external funding or competing interests declared. Previously posted at the *Anaesthesia* Correspondence website: http://www.anaesthesiacorrespondence.com.

References

1 Yentis SM. Research, audit and journal policies. *Anaesthesia* 2011; **66**: 155–6.
2 Shafer SL. Anesthesia & Analgesia policy on Institutional Review Board approval and informed consent for research. *Anaesthesia* 2011; **66**: 157–8.
3 Dixon N. *Review of Ethics Issues Related to Clinical Audit and Quality Improvement Activities*. London: Healthcare Quality Improvement Partnership, 2009. http://www.hqip.org.uk/assets/Downloads/Ethics-and-Clinical-Audit-and-Quality-Improvement-Literature-Review.pdf (accessed 17/05/2011).
4 Dixon N. *Ethics and Clinical Audit and Quality Improvement (QI) – A Guide for NHS Organisations*. London: Healthcare Quality Improvement Partnership, 2009. http://www.hqip.org.uk//ethics-and-clinical-audit-and-quality-improvement (accessed 17/05/2011).

doi: 10.1111/j.1365-2044.2011.06839.x

The 'pecs block': a novel technique for providing analgesia after breast surgery

I read the recent article by Finnerty and colleagues with interest [1] and

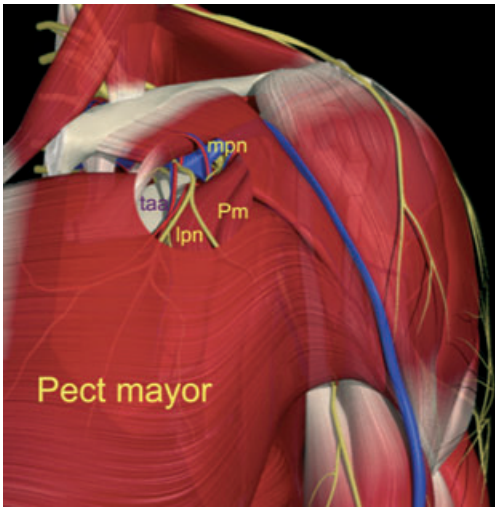

Figure 4 Graphic representation of the area of injection under the pectoralis major muscle. Under the upper part of pectoralis minor (Pm), the pectoral branch of the thoracoacromial artery (taa) is easily identified with the lateral pectoral nerve (lpn) adjacent to it. At that level, the medial pectoral nerve (mpn) is underneath the minor pectoral nerve. (© Primal Pictures, www.primalpictures.com/).

would like to present a novel interfascial plane block. Breast surgery is one of the most common forms of surgery conducted in hospitals. Even relatively minor breast surgery can be associated with significant postoperative pain [2]. Paravertebral blocks have become popular as an alternative to the analgesia provided by the 'gold standard' of thoracic epidural analgesia [3]. However, both regional techniques have complications that make them unsuitable for day surgery, and therefore unsuited to the large proportion of breast surgery patients who are treated on a day-stay basis.

I describe here a simple new alternative approach as a practicable alternative to both paravertebral and epidural blockade in the management of pain after breast surgery. I have called this new block the 'pecs block', as the aim is to place local anaesthetic into the interfascial plane between pectoralis major and minor muscles (Fig. 4). I have performed this block in approximately 50 patients over the last 2 years, and have found that the patients require only minimal analgesia postoperatively (only regular paracetamol and dexketoprofen). The block seems particularly useful for patients who have breast expanders placed during reconstructive breast cancer surgery or subpectoral prostheses.

The anatomical site of the block is superficial and I perform the procedure with a linear ultrasound probe, using a similar probe position to that used when performing an infraclavicular brachial plexus block. Once I have identified the pectoralis major muscle, I check the location of the pectoral branch of the thoraco-acromial artery between the pectoralis muscles with colour Doppler. The lateral pectoral nerve is consistently located adjacent to the artery. I use standard 50-mm block needles to infiltrate the interfascial plane with 0.4 ml.kg^{-1} levobupivacaine 0.25% (Fig. 5). A catheter can readily be placed into the interfascial plane, and I have found 5 ml.h^{-1} infusions of levobupivacaine 0.25% for up to 7 days to be effective. Using this continuous technique, I find opioid analgesia is only very rarely needed in the postoperative period.

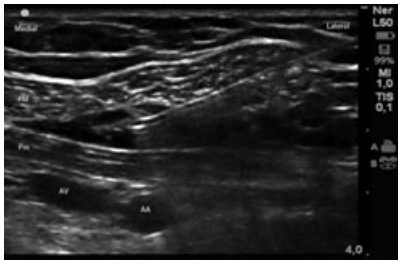

Figure 5 Infiltration into the interpectoral plane at infraclavicular level. PM, pectoralis major and Pm; pectoralis minor muscles; AA, axillary artery; AV, axillary vein.

The 'pecs block' performed under ultrasound guidance is feasible and I have found that patients require little extra analgesia and that the block is suitable in the day-care setting. This now requires formal evaluation of efficacy and safety.

R. Blanco
Complejo Hospitalario Universitario
A Coruna
A Coruna, Spain
Email: rafablanco@mac.com

No external funding or competing interests declared. Figure 4 is published with permission of Primal Pictures (www.primalpictures.com/). Previously posted at the *Anaesthesia* Correspondence website: http://www.anaesthesiacorrespondence.com.

References

1 Finnerty O, Carney J, McDonnell JG. Trunk blocks for abdominal surgery. *Anaesthesia* 2010; **65**: 76–83.
2 Klein SM, Bergh A, Steele SM. Thoracic paravertebral block for breast surgery. *Anesthesia and Analgesia* 2000; **90**: 1402–5.
3 Lynch EP, Welch KJ, Carabuena JM, Eberlein TJ. Thoracic epidural anesthesia improves outcome after breast surgery. *Annals of Surgery* 1995; **222**: 663–9.

doi: 10.1111/j.1365-2044.2011.06838.x

Laryngeal tube suction disposable: a stylet-assisted insertion technique

The laryngeal tube suction disposable (LTS-D; VBM Medizintechnik

 Anaesthesia © 2011 The Association of Anaesthetists of Great Britain and Ireland

Copyright of Anaesthesia is the property of Wiley-Blackwell and its content may not be copied or emailed to multiple sites or posted to a listserv without the copyright holder's express written permission. However, users may print, download, or email articles for individual use.